Case Report

# Unilateral masseter hypertrophy: case report and review running title: unilateral masseter hypertrophy

**Saibaba Mahalakshmi**[1], **Manjula**[2], **Ganganna Kokila**[3], **Likhitha Swamy HR**[4]

[1]Senior Lecturer, Department of Oral Medicine and Radiology,
[2]Senior Dental Health Officer, General Hospital, Magadi Taluk, Ramanagar District
[3]Professor, [4]Senior Lecturer
Department of Oral Pathology and Microbiology,
Sri Siddhartha Dental College and Hospital, Tumakuru,
Sri Siddhartha Academy of Higher Education, Tumakuru.

## Abstract

**Background**: Masseter hypertrophy is characterized by unilateral or bilateral enlargement of masseter muscle producing facial asymmetry or squarish face. Few cases are associated with prominent mandibular angle secondary to muscle hyperactivity. The etiology is unknown; factors predisposed are parafunctional habits, genetic predisposition, sleep disorder, malocclusion and temperomandibular disorders. As reported in literature masseter muscle hypertrophy doesn't require any treatment unless patient is symptomatic or esthetically concerned. Treatment may vary from conservative approach to surgical resection of the involved muscle. **Case detail**: In our case patient presented with pain and swelling on the left lower one third of the face since six months. Examination revealed swelling near insertion of masseter muscle, tenderness in left TMJ, limited mouth opening and deviation of jaw towards affected side on opening mouth. Patient was psychologically disturbed due to disfigurement caused by swelling. As the patient been worried about esthetic, reassurance and psychological counseling was provided and surgical intervention was opted. **Conclusion**: Facial disfigurement not only affects physically but also leads to significant psychological impact, especially in young age group, as it affects the social interaction and confidence of the individual. Understanding the patients need allows the healthcare professionals to provide an appropriate support and to plan suitable treatment needed according to the patient's condition.

**Key words**: Masseter hypertrophy, unilateral masseter hypertrophy, temperomandibular disorder.

## Introduction

The masticatory muscle hypertrophy is identified as asymptomatic benign enlargement of one or more or all the muscles of mastication. Muscle enlargement may be congenital or acquired due to functional hypertrophy.[1] Legg in 1880 first reported bilateral idiopathic masseter and temporalis muscle hypertrophy in a 10-year-old girl[2] where as isolated unilateral enlargement of masticatory muscle is rarely observed.[3] Unilateral masseter muscle enlargement usually

*Address for Correspondence:*
*Dr. S Mahalakshmi, Senior Lecturer, Department of Oral Medicine and Radiology, Sri Siddhartha Dental College & Hospital, Agalakote, Tumkur, Karnataka State, India.*
*E-mail ID; ammisaiganesh@gmail.com*

seen in patient who chew or clench primarily on one side.

Masseter muscle is essential for mastication and is anatomically situated lateral to the mandibular ramus, thus plays an important role in facial esthetics. Masseter muscle hypertrophy (MMH) alters the facial contour leading to square face, prominent mandibular angle which is aesthetically unacceptable to the patient.[1] If such hypertrophy is unilateral it leads to gross asymmetry in lower one third of the face which can be an esthetic concern to the patient seeking medical opinion. Etiology for MMH is unknown, researchers have suggested that masseter hypertrophy may arise due to parafunctional habits like clenching and bruxism associated with psychological factors such as emotional stress, anxiety which may contribute to muscle hyperactivity. Management of MMH ranges from conservative to surgical approach. Occlusal adjustment, occlusal splints, psychological counseling, spasmolytics, tranquilizers, and antidepressant therapy are some of the conservative methods. Surgical therapy is considered gold standard as it provides permanent and more reliable results.[4] This article reports a unilateral masseter hypertrophy in a 25-year old female patient, managed with antidepressant drug and surgically treated.

## Case report:

**History:**

A 25 years old female patient visited to outpatient department with pain in left lower one third of the face since six months and swelling in the same region since two years. Swelling was initially noticed two years back which increased in size gradually to the present size. Pain was intermittent, initiated on chewing, yawning and during wide opening of the mouth particularly in and around left angle of mandible and temporomandibular joint area associated with early morning stiffness of jaw. There was no history of trauma or reduced salivation, patient gave a history of psychological disturbance since a year due to progression of swelling. She was a known betel nut chewer who used to chew eight to ten times a day regularly on the left side of her jaw since eight years. Medical and family history were non contributory.

**Clinical examination:**

Clinical examination revealed gross asymmetry over left angle of the mandible and diffuse swelling in the same region (Fig. 1a & 1b). Left TM Joint was tender, joint movement was smooth on both sides without any clicking sound.




**Fig 1a** : Extra oral view showing the facial asymmetry at the left lower one third of the face and the prominent angle of the mandible




**Figure 1b:** Extra oral view showing swelling at the angle of the mandible

Difficulty in mouth opening and deviation of the jaw towards the ipsilateral side was observed on opening the mouth due to the guarding mechanism of the hyperactive masseter muscle. Swelling was tender on palpation, firm in consistency and became more prominent on clenching the teeth at left masseter muscle region compared to right side. Left pterygoid muscle was tender on functional manipulation. Intraorally full complement of teeth were present. Partially erupted 38 and 48 was seen with no foci of infection, clear and adequate salivary flow was expressed from right and left Stensen's duct. Based on clinical examination a provisional diagnosis of unilateral masseter hypertrophy was considered.

**Investigation:**

Panoramic radiograph was taken to rule out any bony pathology at the angle region. The finding showed a slight prominence of mandibular angle on the left side possibly because of compensatory hypertrophy in the area of muscle insertion (Fig. 2). As OPG revealed no lytic lesion with prominent antigonial notch on the left side. We did not advise for advanced imaging modalities. Based on this finding final diagnosis of unilateral masseter hypertrophy was made.



**Fig 2:** Panoramic view shows prominence of left mandibular angle

**Treatment:**

Patient was advised to quit the betel nut chewing habit and also advised to practice chewing on both sides of the jaw. Muscle relaxants (diazepam 5mg for seven days) were prescribed and referred




**Fig 3a:** Elliptical incision was placed around left angle of the mandible




**Fig 3b:** Resection of hypertrophied masseter muscle

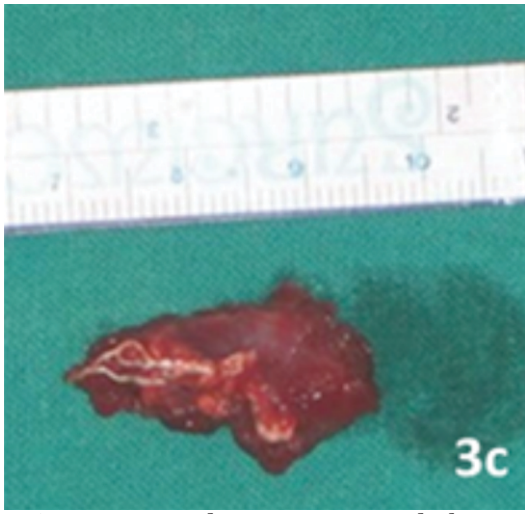


**Fig 3c:** Excised mass measured about 3 x 2 cm in size

for psychiatric consultation. Treatment options were explained. Patient gave consent for surgical treatment, partial resection of left masseter muscle and shaving of mandibular angle was planned. The surgery was performed under general anesthesia with naso-tracheal intubation. Xylocaine 2% with adrenaline was infiltrated in the angle of the mandible. An elliptical incision was placed around the left angle of the mandible (Fig. 3a). The marginal mandibular nerve was identified and protected. Fractional muscle thickness was resected (Fig. 3b & 3c). The bony deformity was trimmed with the surgical bur (Fig. 4a) and sharp margins were trimmed with a bone file (Fig.4b). Primary closure was done with 5-0 prolene suture (Fig. 4c). After one week, the prolene sutures were removed and the wound healed uneventfully.

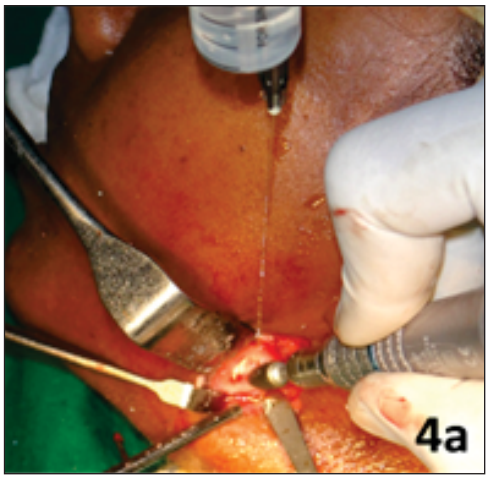


**Fig 4a:** The bony deformity was trimmed with the surgical bur

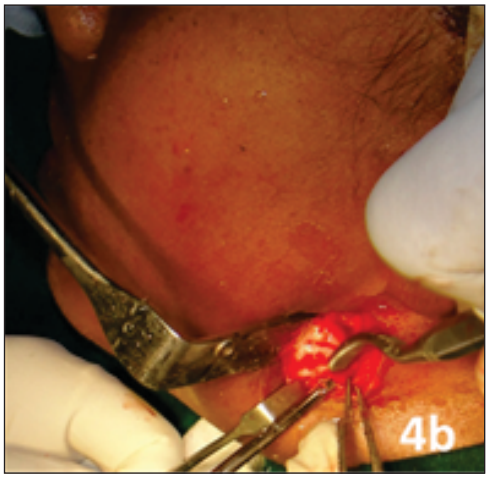


**Fig 4b:** Sharp margins trimmed using a bone file

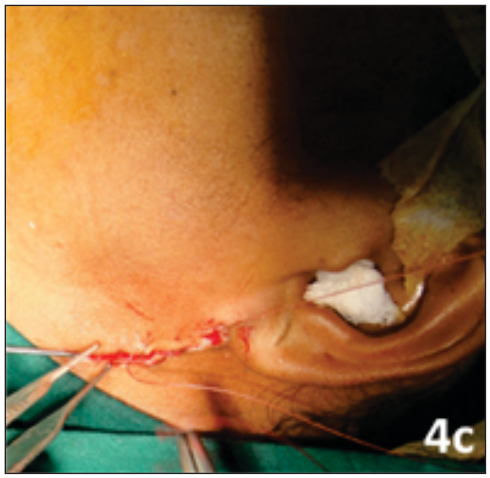


**Fig 4c:** Primary closure done with 5-0 prolene suture

Patient was followed for a year, once in every six months (Fig. 5a-5f). In each follow-up patient was evaluated for joint tenderness, deviation of jaw and masseter muscle tenderness by clenching the teeth. Patient was asked to explain herself regarding her self-assurance of appearance. Patient was satisfied with the treatment outcome both esthetically and functionally.

## Discussion

MMH is benign, asymptomatic with unilateral or bilateral enlargement of masseter muscle. Most of the patients seek treatment for aesthetic concern as bilateral enlargement gives more squarish face, unilateral enlargement results in gross asymmetry.[1] The prevalence of MMH is not clear as there are very few studies on its prevalence Sannomya etal reported that 4% of the patients with masseter hypertrophy were less than 10 years and 3% were over 40 years of age (mean 30 years), with a male to female ratio of 1:1.[5,6] Whereas Beak et al in a review of 180 cases found average age was 30 years, 57% were male, 60% had bilateral involvement with only five patients having concurrent temporalis muscle hypertrophy.[7,8]

The exact etiology is unknown. Literature suggests emotional & psychological factors[4] could attribute to stress induced gum chewing, bruxism and clenching the teeth during night. The extra force exerted during chewing hard

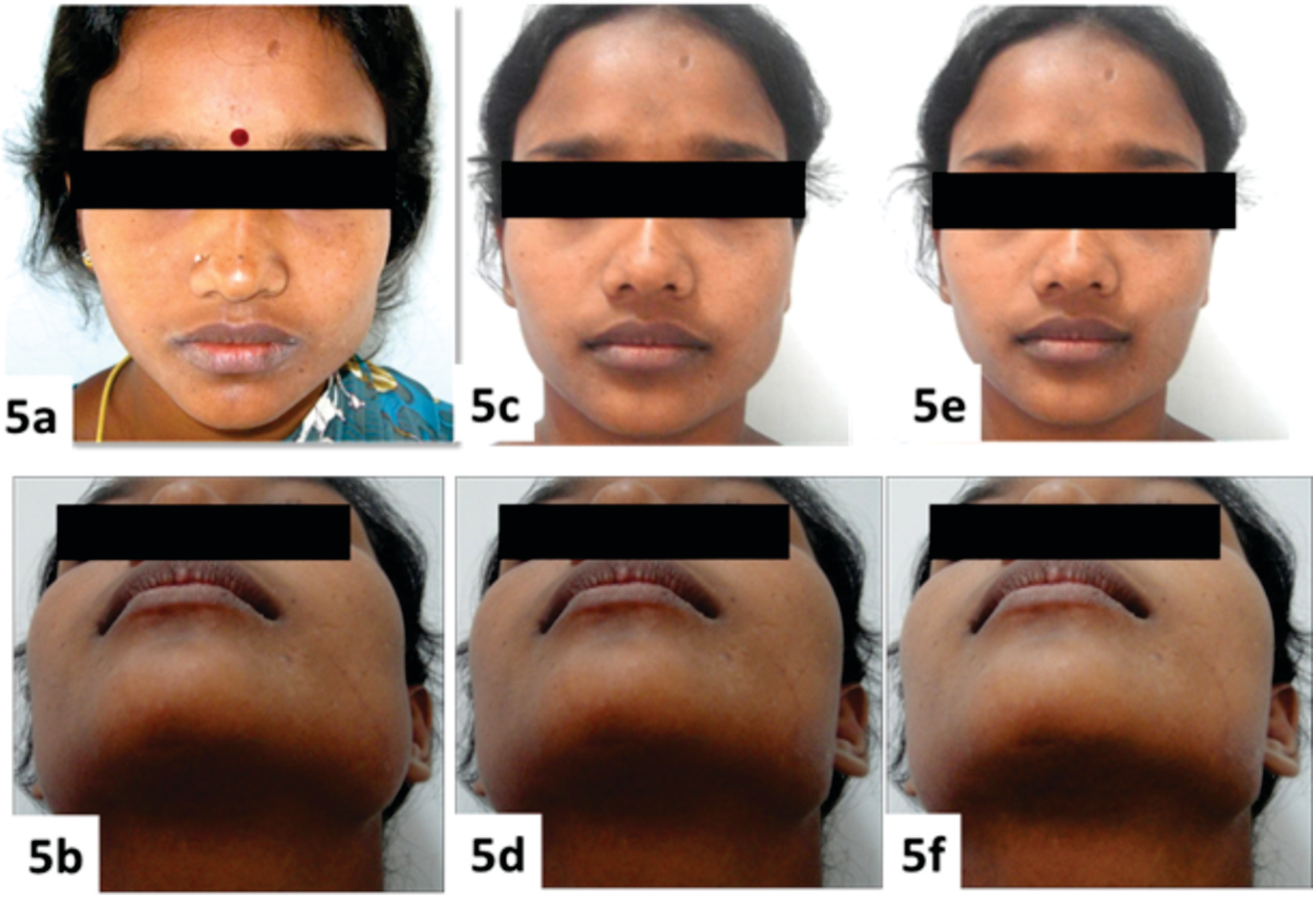


**Fig 5a and 5b:** Preoperative Front profile and submento vertex view showing asymmetry and swelling in the left side of the face
**Fig 5c & 5d:** Two weeks postoperatively shows reduction in swelling
**Fig 5e & 5f:** Six months follow up

foods[9], and genetic basis are also considered.[10] Other possible causes and association are facial hemiatrophy, localized scleroderma and overuse of anabolic steroids.[6]

Clinical examination usually reveals swelling near angle of the mandible, which becomes more prominent on clenching. On palpation hypertrophied muscle at rest is soft and normal tone; at function i.e., during clenching the muscle becomes firm and tense and more evident on the affected side.[6] Hypertrophied muscles modify the function of muscle due to sustained contraction during bruxism /during clenching which may result in pain during yawning, limitation in opening mouth, deflection of the jaw towards the affected side, headache and intermittent masticatory claudication. Few authors have reported that it might mimic temperomandibular disorder due to pressure exerted to joint by hyperactivity of the muscle.[11] Muscular hypertrophy also causes secondary bony enlargement of the mandibular angle from functional remodeling where the muscle gets inserted on bone. Guggenheim and Cohen reported that bone spurs are caused by periosteal irritation and new bone deposition responding to increased forces exerted by the muscle's bundles.[12] The trismus and pain experienced by our patient were related to stress and anxiety episodes. According to the literature, cosmetic alterations are the main complaint of MMH patients. Our patient, however, complained of left TMJ pain on jaw opening but joint movement was found to be smooth without any clicking sound,

pain may be due to muscle dystonia. Case reports also describe masseter muscle and TMJ disorders association with MMH.[11,13-14]

Diagnosis can be achieved from clinical examination, directed interview, morphometric analysis, ultrasonographic, electromyographic measurements and panoramic x-ray. Advanced methods like CT &MRI can be used to rule out other patholgies. In our case, the diagnosis was made by clinical palpation of masseter muscle at the region of insertion. During clenching muscle became more prominent due to contraction.[6]

Various treatment modalities like, psychological counseling, occlusal correction, use of orthotic appliances, antidepressants, anxiolytics, muscle relaxants, injection of botulinum toxin into a muscle and surgical excision of hypertrophied muscle have been reported in the literature with varying degree of success and failure. Medical line of management and psychological counseling is effective for patient with mild hypertrophy, but there is no reliable report on the success rate. Botulium toxin has shown good results in various studies, but biggest limitation is recurrence of the condition within 6 months.[15] Surgical excision is the treatment of choice for MMH as it gives permanent relief in symptomatic cases as well as patients with cosmetic concern.[4] Surgery can be done either intra orally or extra orally. Excision of hypertrophied muscle and trimming or sectioning of thickened bone at the angle of mandible is the chosen treatment protocol. In our case we opted for surgery as patient was symptomatic and psychologically disturbed due to esthetic concern as a result of swelling.

## Conclusion

Unilateral masseter hypertrophy alters the facial contour line resulting in negative cosmetic impact in many patients. A pleasing appearance today is a part of the reality of social acceptability. Disfigurement as a result of MMH has significant psychological impact especially in younger generation. In this report we presented a case managed with psychological counseling and surgical intervention. Satisfactory esthetic improvement was achieved which in turn improved the self confidence of the patient.

**Financial support and sponsorship**: NIL

**Conflict of Interest**: The authors have no conflict of interest.

## References

1. Ozturk E, Mutlu H, Sonmez G,Sildiroglu HO, Basekim CC, Kizilkaya E. Unilateral temporalis muscle hypertrophy with contralateral masseteric hypertrophy. Dentomaxillofacial Radiology 2007; 36: 296–7.
2. Legg W. Enlargement of the temporal and masseter muscle in both sides. Jr Path Soc London 1880;63(5):361-4.
3. Mandel L, Tharakan M. Treatment of unilateral masseteric hypertrophy with botulinum toxin: case report. J Oral Maxillofac Surg 1999; 57: 1017–19.
4. Daniel ZR, Paulo MC, Jose LP, Vinicius RF, Karina KM, Marcela AC. Benign masseter muscle hypertrophy. Rev Bras Otorrinolaringol. 2008; 74(5): 790–3.
5. Sannomya EK, Gonçalves M, Cavalcanti MP. Masseter muscle hypertrophy: case report. Brazilian Dental Journal 2006;17(4): 347–50.
6. Al-MuharraqiMA, Fedorowicz Z, Al Bareeq J, Al Bareeq R, NasserM. Botulinum toxin for masseter hypertrophy. Cochrane Database of Systematic Reviews 2009; 1: 1-13.
7. Baek SM, Kin SS, Bindiger A. The proeminent mandibular prospective, management, operative technique and results in patients. Plast Reconst Surg 1989;83:272.
8. Rispoli DZ, Camargo PM, Pires JL Jr, Fonseca VR, Mandelli KK, Pereira MA. Benign masseter muscle hypertrophy. Braz J Otorhinolaryngol 2008;74:790-3.
9. Jin Park Y, Woo Jo Y, Bang SI, Kim HJ, Lim SY, Mun GH, et al. Radiofrequency volumetric reduction for masseteric hypertrophy. Aesthetic Plastic Surgery 2007; 31(1): 42–52.
10. Kitagawa Y, Hashimoto K, Kuriyama M. Hypertrophic branchial myopathy with uniform predominance of type 1 fibres. Case report. Scandinavian journal of plastic and reconstructive

surgery and hand surgery 2000; 34(4): 391–6.

11. Chikhani L, Dichamp J. Bruxism, temporo-mandibular dysfunction and botulinum toxin. Annales de Réadaptation et deMédecine Physique 2003; 46(6): 333–7.
12. Guggenheim P, Cohen L. Masseteric hypertrophy. Arch Otolaryngol 1959; 70: 674-680.
13. Fyfe EC, Kabala J, Guest PG. Magnetic resonance imaging in the diagnosis of asymmetrical bilateral masseteric hypertrophy. Dentomaxillofac Radiol 1999;28:52-4.
14. Jimenez LF. Difficult intubation in a patient with benign masseteric muscle hypertrophy. British J Anaesthesia; 2001.
15. Baş B, Ozan B, Muglali M, Çelebi N. Treatment of masseteric hypertrophy with botulinum toxin: A report of two cases. Med Oral Patol Oral Cir Bucal. 2010; 15(4): e649-52.

**How to cite this article**:
Mahalakshmi S, Manjula, Kokila G, Likhitha Swamy HR. Unilateral masseter hypertrophy: case report and review. JDSR. 2020 Sept;7(2):14-20.